

JOURNAL OF CLINICAL AND DIAGNOSTIC RESEARCH

How to cite this article:

BASAK S , BOSE S, MALLICK S K , GHOSH A K .INTESTINAL PARASITIC INFECTIONS IN HIV SEROPOSITIVE PATIENTS -A STUDY. Journal of Clinical and Diagnostic Research [serial online] 2010 June [cited: 2010 June 7]; 4: 2433 - 2437.

Available from

http://www.jcdr.net/back_issues.asp?issn=0973-709x&year=2010 &month=June &volume=4&issue=3&page= 2433 - 2437 &id=633

ORIGINAL ARTICLE

Intestinal Parasitic Infections In HIV Seropositive Patients – A Study

BASAK S *, BOSE S**, MALLICK S K***, GHOSH A K****

ABSTRACT

Opportunistic infections are the hallmark of the Human Immuno Deficiency Virus (HIV) infection. In recent years, intestinal infections such as *Cryptosporidium*, *Cyclospora* and *Isospora* are becoming more prevalent in Acquired immunodeficiency syndrome (AIDS) patients. *Strongyloides stercoralis* infections can lead to the hyperinfection syndrome and even to lethal disease in immunosuppressed patients. The present study was undertaken to study the prevalence of parasitic infections in HIV seropositive patients.

Out of 268 stool samples, 148, stool samples were collected from HIV seropositive patients with diarrhoea and 120 stool samples were collected from HIV seronegative patients with diarrhoea. All the 268 stool samples were examined by wet mount preparation (saline, Lugol's iodine) and staining (modified Ziehl Neelsen staining) for the detection of the parasitic infection.

The total number of intestinal coccidian parasite was 52 (35.1%)(in HIV seropositive patients. No intestinal coccidian parasite was found in HIV seronegative patients. Co-infection with *Cryptosporidium*, *Isospora* and *Cyclospora* was observed in three (2%) of the HIV seropositive cases. However, the larva of *Strongyloides stercoralis* was found in two (1.4%) of the HIV positive patients and both the patients had chronic diarrhoea.

Key Words: Intestinal coccidian parasite, HIV infection, Diarrhoea.

(M.D), (M.D), Professor of Microbiology ,***
(M.B.B.S.) Tutor Deptt. of Microbiology,****
(M.D.) Professor of MedicineJawaharlal Nehru
Medical College, Sawangi (M) Wardha (M.S)
Corresponding Author:
Dr. Silpi Basak, M.D
Professor of Microbiology
Jawaharlal Nehru Medical College, Sawangi (M)
Wardha (India)Phone: (07152) 287765
Mobile: 09421726385
E-mail: drsilpibasak@gmail.com.

Introduction

Acquired Immunodeficiency Syndrome (AIDS) is the major global public health problem of the 21st century. Worldwide, an estimated 33 million people are living with HIV infection [1]. This is alarming due to the unique pathogenesis of HIV that mainly affects the CD₄⁺ T helper cells and hence,

opportunistic infections are the hallmark of HIV infection. The World Health Organization (WHO) defines diarrhoea wasting syndrome along with HIV seropositivity as AIDS defining illness [2]. The opportunistic coccidian parasites like *Cryptosporidium*, *Isospora*, *Cyclospora*, etc. cause diarrhoea in almost 90% of AIDS patients in developing countries [3].

Hence, the present study was undertaken to study the prevalence of intestinal parasitic infections in HIV seropositive patients with diarrhoea.

Material And Methods

The study was conducted from January 2008 to December 2008. HIV seropositive patients were defined as those who had been

tested positive for HIV antibodies by any of the two tests (i.e. ELISA/Rapid/Simple) as per the recommendations given by WHO [4].

A total of 268 stool samples of 148 HIV seropositive and 120 seronegative patients were included in this study. Diarrhoeal stool samples of HIV seropositive and HIV seronegative patients were examined by wet mount preparation (saline and Lugol's iodine) and modified acid fast staining [5] to detect parasitic infections. Modified acid fast staining was specifically done to detect intestinal coccidian parasites e.g. *Cryptosporidium*, *Isospora belli* and *Cyclospora* species. No special staining for *Microsporidia* was included in the study. Persistence of diarrhoea for more than 4 weeks in a patient was defined as chronic diarrhoea [6].

Result

A total number of 268 diarrhoeal stool samples of 148 HIV seropositive patients and 120 HIV seronegative patients were examined for the detection of intestinal parasitic infections. Amongst 148 HIV seropositive patients, 96 had chronic diarrhoea and 52 patients had diarrhoea of an average of three-seven days duration, whereas HIV seronegative patients had diarrhoea of an average of two-four days duration. Only one stool sample from each patient was collected.

The number of HIV seropositive patients who attended the O.P.D with diarrhoea twice and thrice during the study period with an average interval of one and a half months was five and two, respectively. Out of these five seropositive patients, two had *Cryptosporidium* infection and one patient had infection with *Entamoeba histolytica* on both the occasions, whereas two other patients had infection with *Entamoeba histolytica* on the first visit, but developed *Isospora belli* infection on the second visit. Two patients who attended the OPD thrice at average intervals of one and a half months

had *Entamoeba histolytica* infection on all the three occasions.

The total number of intestinal parasites observed in the stool samples of HIV seropositive patients was 87(58.8%) (Table/Fig1) as compared to 36 (30 %) in the stool samples of HIV seronegative patients (Table/Fig 2). The number of opportunistic infections with the intestinal coccidian parasite was 52 (35.1 %) in HIV seropositive patients, out of which co-infection with *Cryptosporidium*, *Isospora* and *Cyclospora* was observed in three (2 %) cases. *Cryptosporidium* sp. was found in 42 cases (28.4 %), followed by *Isospora belli* seven in cases (4.7%), *Cyclospora* sp in three cases (2%) [Table/Fig 3], [Table/Fig 4], [Table/Fig 5] and other protozoal pathogens e.g. *Entamoeba histolytica* was present in 21 cases (14.1 %) and *Giardia lamblia* in 12 (8.1 %) of HIV seropositive cases. Mixed infections with *Entamoeba histolytica* and *Giardia lamblia* was found in four (2.7%) HIVseropositive cases. The larva of *Strongyloides stercoralis* was found in two (1.4 %) of the HIV positive patients and both the patients had chronic diarrhoea [Table/Fig 6]. Out of 52 intestinal coccidian parasitic infections, 29 (55.8%) were present in HIV positive patients with chronic diarrhoea.

No coccidian parasite was found in the stool samples of HIV seronegative patients (Table/Figure: 2). *Entamoeba histolytica* was found in 26 cases (21.7 %), followed by *Giardia lamblia* in seven cases (5.8 %). The ova of *Ascaris lumbricoides* was found in one case (0.8%) and the ova of *Hymenolepis nana* was found in one case (0.8%) in the HIV negative patients. Two HIV seronegative patients had mixed infection with *Entamoeba histolytica* and *Giardia lamblia*. The larva of *Strongyloides stercoralis* was found in one (0.8 %) of the HIV negative patients who was 80 yrs old and was having diarrhoea for more than eight days [Table/Fig 7].

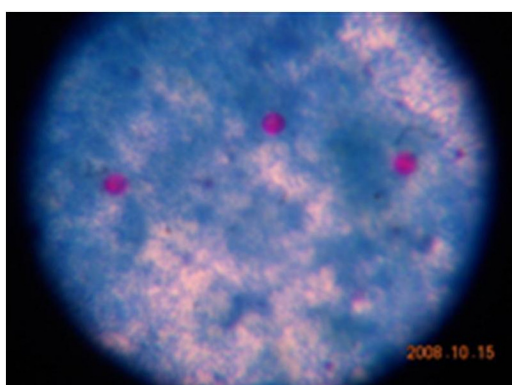
The CD₄⁺ T cell count was done in only 33 HIV seropositive patients due to financial constraints and due to lack of the patients' compliance. Out of these 33 patients, 29 patients had intestinal coccidian parasitic infection. The CD₄⁺ T cell count was 500 to 200 cells/mm³ in five patients (17.2%), 200 to 100 cells/mm³ in twelve (41.3%) patients, 100 to 50 cells/mm³ in seven (24.1%) patients and <50 cells/mm³ in three (10.3%) patients with intestinal coccidian parasitic infection respectively.. Two patients having cryptosporidium infection had a normal CD₄⁺ T cell count (616 and 589 cells/mm³) respectively.

(Table/Fig 1)Prevalence of intestinal parasitic infection in HIV seropositive patients with diarrhoea n= 148

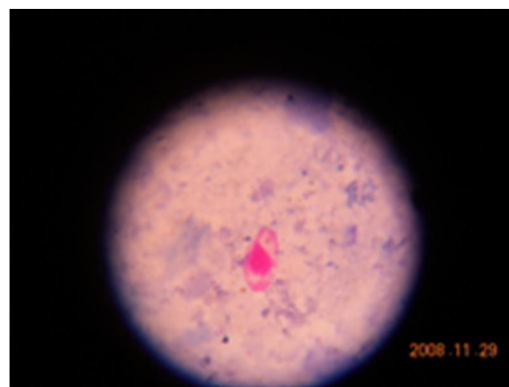
HIV positive number	Total intestinal parasites		Intestinal Coccidian parasites	
	number	percentage	number	percentage
148	87	(58.8%)	52	(35.1%)

(Table/Fig 2)Prevalence of intestinal parasitic infection in HIV seronegative patients with diarrhoea

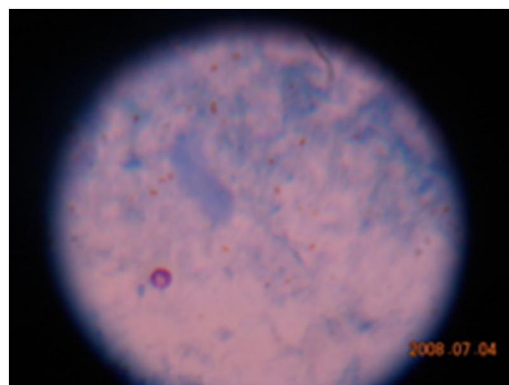
HIV negative no.	Intestinal parasitic infection no. percentage		Intestinal Coccidian parasitic infection no.
	no.	percentage	
120	36	(30%)	0



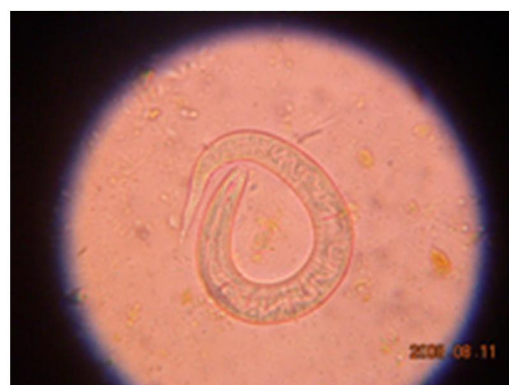(Table/Fig 3)Showing oocyst of Cryptosporidium spp



(Table/Fig 4)Showing oocyst of Isospora belli



(Table/Fig 5)Showing oocyst of Cyclospora spp.



(Table/Fig 6)Showing larva of Strongyloides stercoralis with double bulb esophagus

SL no	Parasite	HIV positive		HIV negative	
		no.	percentage	no	percentage
1.	<i>Cryptosporidium</i>	42	(28.4%)	0	
2.	<i>Isospora belli</i>	7	(4.7%)	0	
3.	<i>Cyclospora</i>	3	(2.02%)	0	
4.	<i>Entamoeba histolytica</i>	21	(14.1%)	26	(21.7%)
5.	<i>Giardia lamblia</i>	12	(8.1%)	7	(5.8%)
6.	<i>Ascaris lumbricoides</i>	0		1	(0.8%)
7.	<i>Hymenolepis nana</i>	0		1	(0.8%)
8.	<i>Strongyloides stercoralis</i>	2	(1.35%)	1	(0.8%)
	TOTAL	87	(58.8%)	36	(30%)

(Table/Fig 7)Prevalence of different intestinal parasitic infection in HIV positive and HIV negative patients with diarrhea.

Discussion

Among the opportunistic infections, intestinal parasitic disease is the commonest and is a major cause of morbidity and mortality in HIV positive individuals worldwide [7]. The coccidian parasites i.e. *Cryptosporidium sp*, *Isospora belli*, *Cyclospora sp*. and *Microsporidium sp*. are known to cause life-threatening profuse watery diarrhoea in HIV positive individuals because of their low immune status [8].

In our study, the coccidian parasites were found in HIV seropositive patients only and *Cryptosporidium sp*. (28.4%) was the most common, followed by *Isospora belli* (4.7%). In 2002 and 2005, two reports from North India [9],[10] had also reported *Cryptosporidium sp*. to be the most common coccidian parasite in HIV positive patients. Similarly, in another study conducted in the Centre for AIDS and related diseases, National Institute of Communicable Diseases, Delhi, Dwivedi et al had reported that *Cryptosporidium sp* was predominant (63.9%) and *Isospora belli* was present in only 4% of the HIVseropositive patients with diarrhoea [11]. *Cryptosporidium sp*. was the most common parasite (25%), followed by *Isospora belli* in 20% of the patients who have been reported from CMC, Vellore [12]. But Gupta et al in 2008, had reported from North India about the preponderance of *Isospora belli* (50%), followed by *Cryptosporidium sp*. (23.6%) in HIV positive patients [13]. Similarly, the higher prevalence of *Isospora belli* as compared to *Cryptosporidium sp*. have been reported from South India [3],[14].

The five HIV seropositive patients who showed the same parasite infection when they attended the OPD twice or thrice at one and a half month intervals, may have been infected because of their unhygienic living conditions. One HIV positive female patient aged 28 years had infection with *Cryptosporidium sp*. and was treated for that, but continued to have watery diarrhoea and was found to have lactose intolerance also.

In a country of 2.5 million HIV positive adults, India is now facing the HIV epidemic [15]. Screening of the coccidian parasite is still not done as a routine test in HIV positive patients in most of the Microbiology Laboratories, but a good number of HIV seropositive patients suffer from diarrhoea due to coccidian intestinal parasites.

Hence, to conclude, routine screening of the stool samples of HIV seropositive patients with diarrhoea should be done for prompt patient care, to prevent the fulminant form of the disease. As most of the opportunistic parasitic infections occur through the faecal oral route, they can be prevented by using safe drinking water and food, by maintaining personal hygiene and by avoiding walking bare foot.

Acknowledgement

The authors highly acknowledge Datta Meghe Institute of Medical Sciences University (M.S) for funding the project.

References

- [1] World Health Organization, Regional office for South-East Asia. News bulletin on HIV burden, Lead empower deliver on World AIDS day, 1st December 2008.
- [2] WHO case definitions of HIV for surveillance and revised clinical staging and immunological classification of HIV-related disease in adults aged 15 years or older. SEARO publications on HIV/AIDS: 2006. Available from <http://www.searo.who.int>.
- [3] Mukhopadhyaya A, Ramakrishna BS, Kang G, Pulimood AB, Mathan MM, Zachariah A, et al. Enteric pathogens in southern India HIV-infected

patients with and without diarrhoea. Indian J Med Res 2005; 97: 270-3.

[4] UNAIDS/WHO. UNAIDS/WHO Recommendations. The importance of simple/rapid assays in HIV testing. Weekly Epidemiological Record. 1998; 73:321-28.

[5] Forber B.A., Sahn D.F., Weissfeld A.S. Laboratory methods for diagnosis of Parasite infections, In: chapter 49, Bailey and Scott's Diagnostic Microbiology 12th ed. Mosby Elsevier publisher, International edition, 2007:622.

[6] Smith PD, Lane HL, Gill VG, Manilchewitz JF, Quinnan GV, Fauci AS, et al. Intestinal infections in patients with AIDS. Etiology and response to therapy. Ann Intern Med 1988; 108: 328-33.

[7] Chaisson RE, Gallant JE, Keruly JC, Moor RD. Impact of opportunistic disease on survival in patients with HIV infection. AIDS 1998; 12: 29-33.

[8] Meisel JF, Perera DR, Meligrilo C, Rubin CB. Overwhelming watery diarrhoea associated with cryptosporidium in an immunosuppressed patient. Gastroenterology 1976; 70: 1156-66.

[9] Mohandas K, Sehgal R, Sud A, Malla N. Prevalence of intestinal parasitic pathogens in HIV-seropositive individuals in Northern India. Jpn J Infect Dis 2002; 55: 83-4.

[10] Sadraei J, Rizvi MA, Baveja UK. Diarrhea, CD4⁺ cell counts and opportunistic protozoa in Indian HIV-infected patients. Parasitol Res 2005; 97:270-3.

[11] Dwivedi KK, Prasad G, Saini S, Mahajan S, Lal S, Baveja UK. Enteric opportunistic parasite among HIV infected individuals associated risk factors and immune status. Jpn. J. Infect. Dis., 2007; 60: 76-81.

[12] Rao Ajjampur S.S., Asirvatham J.R., Muthusamy D., Gladstone B.P., Abraham O.C., Mathai D., Ward H., Wanke C., Kang G. Clinical features & risk factors associated with cryptosporidiosis in HIV infected adults in India. Indian J Med Res 2007; 126: 553-7.

[13] Gupta S, Narang S, Nunavath V, Singh S. Chronic diarrhoea in HIV patients: prevalence of coccidian parasites. Indian J Med Microbiol 2008; 26(2): 172-5.

[14] Kumar SS, Ananthan S, Lakshmi P. Intestinal parasitic infection in HIV infected patients with diarrhoea in Chennai. Indian J Med Microbiol 2002; 20(2): 88-91.

[15] Press release, New Delhi 06 July 2007, National AIDS control organization, Ministry of Health & Family welfare, Govt. of India. Available from <http://www.nacoonline.org>.