

Successful Resuscitation of a Cardiac Arrest following Slit Neck and Carotid Artery Injury: A Case Report

SAYYED EHTESHAM HUSSAIN NAQVI¹, ERAM ALI², MOHAMMED HANEEF BEG³, SAURAV VARSHNEY⁴

ABSTRACT

Carotid artery injuries constitute a specific and relatively small group of vascular trauma among the traumatic injuries to neck. They have the potential of killing the patients within minutes to hours due to haemodynamic instability if not managed by the specialist team within time. Central Neurologic deficit from cerebral hypoxia either resulting primarily from trauma or secondarily from surgery is a major concern. We hereby present a case of a 22-year-old man who presented to emergency department with alleged assault and vascular trauma to neck in a state of cardiac arrest. On exploration patient had injuries to external and internal carotid arteries and external jugular vein. Combined effort of trauma team lead to successful resuscitation and saved the life of the patient.

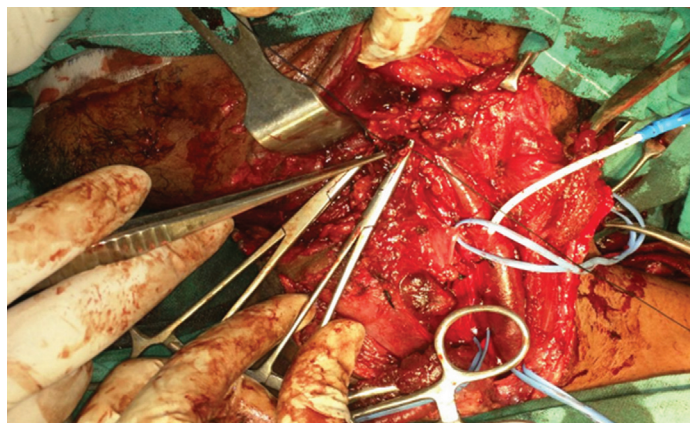
Keywords: Slit throat injury, Vascular trauma neck, Cardiopulmonary resuscitation

CASE REPORT

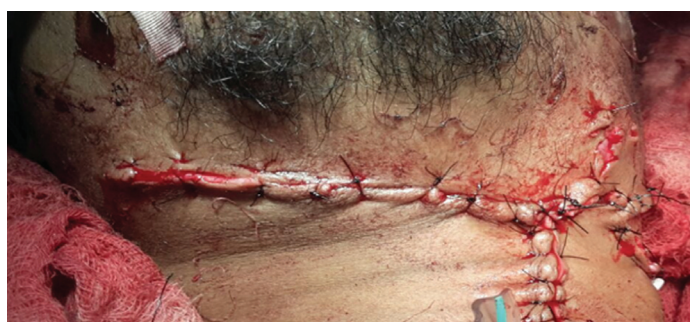A 22-years-old male was brought to emergency of our hospital with history of alleged assault, with slaughtered neck from the left side with some sharp object. Cause of assault was not disclosed by the patient's attendants. On examination in hospital patient was in a state of cardiac arrest with laceration over the left lateral neck in the zone II with overlying large blood clot. An urgent call was send by casualty medical officer to vascular surgery unit. Cardio-pulmonary resuscitation was immediately started. Patient was intubated and chest compressions continued as the patient was rushed to emergency OT. Bilateral saphenous venous cut downs were done, fluid resuscitation started and injection adrenaline and soda bicarbonate was given intravenously. After 4-5 minutes of chest compression cardiac activity was observed on ECG and auscultation. Meanwhile neck exploration started by vascular surgery team showed active bleed from four different positions which were secured by applying vascular clamps and neck exploration started from proximal aspect. Intravenous unfractionated heparin was given. Skin incision was given anterior to sternocleidomastoid, platysma divided and carotid sheath identified. Sternocleidomastoid was divided for better and urgent visualization of carotid and internal jugular vein. Great vessels were identified and looped. Central venous catheter was inserted in internal jugular vein by open technique and inotropes and fluid management was started from central venous line. Patient had acceptable haemodynamic parameters by this time. Packed RBCs were arranged and transfused. Vascular repair was then started. Examination of wound, on applying clamps revealed transected superior thyroid artery, rent in internal carotid artery and transected external jugular vein. Superior pole of thyroid was actively bleeding. Trachea and oesophagus were intact. Right carotid and internal jugular vein were also found to be uninjured [Table/Fig-1].

Superior thyroid artery and external jugular vein were ligated, internal carotid artery rent was repaired using prolene 6-0 and bleeding thyroid pole was ligated. After acceptable haemostasis sternocleidomastoid was repaired and wound closed inlayers [Table/Fig-2].

Patient was extubated next day morning with stable haemodynamics and no cranial nerve deficit [Table/Fig-3].



[Table/Fig-1]: Showing avulsed superior thyroid pedicle with transected superior thyroid artery, injured ICA secured with clamp and transected EJV.

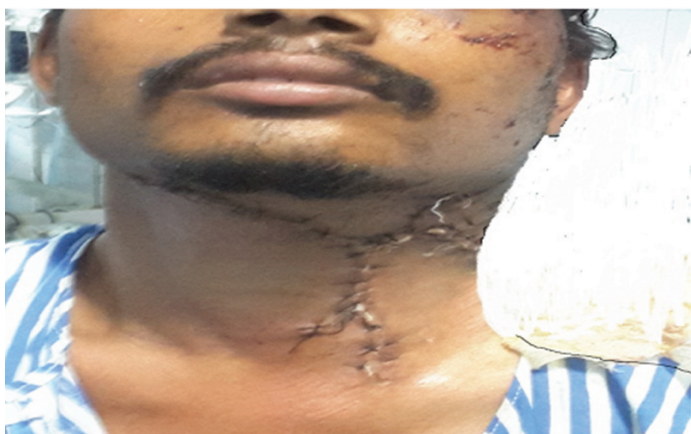

[Table/Fig-2]: Showing completed repair after skin closure.

DISCUSSION

Traumatic injuries to the neck are some of the unusual but potentially lethal situations encountered by trauma surgeons and intensivists. A wide range of vital structures including trachea, oesophagus, carotid artery, internal jugular vein or cranial nerves can be injured by a single laceration over this anatomically important region of the body [1]. Patient often reach hospital emergencies in critical state and demand highest degree of coordination and excellence from the trauma management team.

Traumatic injuries to the neck comprise a comparatively smaller proportion as compared to trauma to other parts of the body. A study reported from a single centre in USA showed that neck



[Table/Fig-3]: Showing patient just before discharge.

trauma comprise around 1% of all patients presenting to trauma centre [2]. However, these injuries have a substantial potential of creating mortality and morbidity if not intervened promptly. They can lead to patient's exsanguination between minutes and hours. These injuries can be a result of both blunt and penetrating trauma. Both mechanisms can cause devastating injuries. Unfavourable outcomes of penetrating injuries are usually dramatic. On the other hand blunt injuries usually present in a more subtle and delayed manner [3]. In the present case, the patient had suffered a penetrating injury. He was assaulted with a sharp object and had a large laceration wound over the left side of neck. He was in a state of cardiac arrest when attended in the emergency department.

A wide range of vital structures including trachea, oesophagus, carotid artery, internal jugular vein or cranial nerves can be injured in patients of penetrating neck trauma. In our case patient didn't have a injury to trachea or oesophagus but had major injuries to carotid arterial system and external jugular vein. Demetriades et al., reported in his evaluation of 223 patients with penetrating neck trauma that the following structures were injured [1]: 40% patients having no significant damage, major vein were involved in 15-25% cases, major artery in 10-15% cases, digestive tract (pharynx, oesophagus) in 5-15%, respiratory tract (larynx, trachea) 4-12% and major nerves in 3-8% cases.

For the purpose of Location, Traumatic injuries to neck can be classified in to 3 zones [4].

- Zone I – from sternal notch to cricoid (possible injuries to trachea, great vessels, oesophagus, thoracic duct, upper mediastinum and lung apices).
- Zone II – cricoid to angle of mandible (possible injuries to carotid and vertebral arteries, jugular veins, oesophagus, pharynx, trachea and larynx).
- Zone III – angle of mandible to base of skull (possible injuries to distal extracranial carotid arteries, vertebral arteries and jugular veins).

In our patient laceration was localized to zone II injuring the major neck vessels leading to extensive haemorrhage, hypovolemic shock and ultimately cardiac arrest.

Injury to carotid arterial and jugular venous system was the most challenging aspect in our case to the trauma team. Haemorrhage from the carotid vessels with 10% of total cardiac output flow can cause a fatal haemorrhagic shock or severe neurological deficit [5]. It is always a concern that interruption of blood flow to the cranial vessels, may lead to focal brain ischemia. Moreover restoration of blood flow may cause haemorrhage in the area of ischemia and worsen the extent of brain injury by converting an ischemic infarct into a haemorrhagic infarct [3]. Mortality rates due to such vascular injuries vary between 5-50% [6-8].

Application of vascular clamps over the bleeding vessels is often the first step by a vascular surgeon. It improves the visibility of the existing injuries and prevents further blood loss. But in case of carotid vessels a note of caution should be observed. Neurologic deficit due to cerebral hypoxia resulting primarily from trauma or secondarily from surgery is a major concern [9].

Management of the patient with carotid injuries has varied aspects. Patients with carotid artery injuries should be considered for surgical repairs in subjects who have either no neurologic deficit, or have only a mild deficit. This decision is easier to reach when the arterial injury is bleeding briskly, but may be more difficult when there is complete carotid occlusion and there are no neurologic symptoms [10].

Dictum for management is that simple injuries to the external carotid artery should be repaired and complex injuries ligated. Complex injuries to common carotid artery can be ligated with risks of neurologic deficits [6]. Injuries to the internal carotid artery are more problematic. In a few patients arterial wall may be so extensively damaged so that reconstruction cannot be accomplished. If the distal backflow and the distal carotid blood pressure are adequate, carotid ligation can be safely done [6]. This does not universally holds good, because even if initially tolerated distal internal carotid artery thrombosis may lead to a stroke and cerebral injury [11]. Extra-cranial to intracranial bypass grafts have been reported by few authors when inaccessible lesions of the intrapetrous portion of the internal carotid artery are present [12]. In the present case, we were able to repair the internal carotid artery as the damage was not extensive. Bleeding superior thyroid artery and external jugular vein was successfully ligated.

In case of haemodynamically stable patients arteriographic examination of the extra cranial vessels should be done early in the diagnostic evaluation. But in our case due to haemodynamic instability, patient had to be directly taken to OT.

We heparinized the patient using unfractionated heparin during surgery and continued it in the postoperative period in the dose of 100 IU/Kg thrice a day for 3 days. Heparin has been found to have role in controlling the rate and extent of carotid thrombosis following occlusion, or proximal ligation. A lower stroke rate has been found in a small series of patients treated with heparin while awaiting definitive surgery for occlusive disease [10].

We could not do a postoperative carotid angiogram. However, following completion of the arterial repair a carotid arteriogram should be obtained to assess the distal intracranial circulation and to be certain that no residual clots are present in the carotid system.

Another cause of concern for us was the neurological recovery of the patient after successful repair and resuscitation. It is well known that outcome of carotid vascular injuries in case of penetrating neck trauma depends largely on the extent of the initial neurologic damage. Patients who have severe neurologic deficits associated with alterations in consciousness, or patients with total interruption of carotid flow cannot be improved by carotid repair [9]. Unilateral carotid injury and clamping was the probable cause of favourable outcome leading to neurological recovery in our case.

CONCLUSION

Vascular injuries of neck can be a cause of serious morbidity and mortality. These injuries should be intervened immediately using a team approach and should be followed seriously during postoperative period. Patients who do not have a stable condition, who have hematoma and serious bleeding should be immediately taken for surgery. Patient with in hospital cardiac arrest with team resuscitation and simultaneous surgical repair may have a good survival outcome as is evident from our case.

REFERENCES

- [1] Demetriades D, Theodorou D, Cornwell E, Berne TV, Asensio J, Belzberg H. Evaluation of penetrating injuries of the neck: prospective study of 223 patients. *World J Surg.* 1997;21(1):41-48.
- [2] Brywczyński JJ. Management of penetrating neck injury in the emergency department: a structured literature review (metaanalysis of 20 studies). *Emerg Med J.* 2008;25:711-15
- [3] Towne JB, Neiss DD, Smith JW. Thrombosis of the internal carotid artery following blunt trauma. *Arch Surg.* 1972;104:965-68.
- [4] Joseph P, John AB, James JS, Preston F. Mandatory vs selective exploration for penetrating neck trauma. *A Prospective Assessment Arch Surg.* 1987;122(5): 592-97.
- [5] Dorobisz AT, Stepinski P. Injuries of carotid arteries. *Zentralbl Chir.* 2004;129(1): 12-20.
- [6] Fry RE, Fry WJ. Extracranial carotid artery injuries. *Surgery.* 1980;88:581-87.
- [7] Daniel F, Gerrit D, Shabbir A, Brian L. Neurologic outcome after penetrating extracranial arterial trauma. *Journal of Vascular Surgery.* 2003;38:257-62.
- [8] Johnston RHJ, Wall MJJ, Mattox KL. Innominate artery trauma: a thirty-year experience. *J vascsurg.* 1993;17:134-39.
- [9] Bradley EL. Management of penetrating carotid injuries: an alternative approach. *J Traum.* 1973;13:248-55.
- [10] Payan HM. III effects of carotid artery ligation: experimental study on influence of age. *Ann Surg.* 1967;165:545-50.
- [11] Goldstone J, Moore WS. Emergency carotid artery surgery in neurologically unstable patients. *Arch Surg.* 1976;111:1284-91.
- [12] Papp AJ, Chater N. Extracranial-to-intracranial vascular anastomosis for occlusive cerebrovascular disease: experiences in 110 patients. *Surgery.* 1977;82:648-54.

PARTICULARS OF CONTRIBUTORS:

1. Assistant Professor, Department of Cardiothoracic and Vascular Surgery, Jawaharlal Nehru Medical College, A.M.U, Aligarh, Uttar Pradesh, India.
2. Senior Resident, Department of Obstetrics and Gynecology, Jawaharlal Nehru Medical College, A.M.U, Aligarh, Uttar Pradesh, India.
3. Professor, Department of Cardiothoracic and Vascular Surgery, Jawaharlal Nehru Medical College, A.M.U, Aligarh, Uttar Pradesh, India.
4. Junior Resident, Department of Cardiothoracic and Vascular Surgery, Jawaharlal Nehru Medical College, A.M.U, Aligarh, Uttar Pradesh, India.

NAME, ADDRESS, E-MAIL ID OF THE CORRESPONDING AUTHOR:

Dr. Sayyed Ehtesham Hussain Naqvi,
Assistant Professor, Department of Cardiothoracic and Vascular Surgery, Jawaharlal Nehru Medical College,
A.M.U, Aligarh, Uttar Pradesh-202002, India.
E-mail: drehtesham.naqvi@gmail.com

FINANCIAL OR OTHER COMPETING INTERESTS: None.

Date of Submission: **Dec 31, 2015**

Date of Peer Review: **Apr 05, 2016**

Date of Acceptance: **Apr 28, 2016**

Date of Publishing: **Jun 01, 2016**