

Nasal Conidiobolomycosis- The Unknown Threat

NIKHIL ARORA¹, EISHAAN K. BHARGAVA², VARUN RAI³

Keywords: *Conidiobolus coronatus*, Entomphthoromycosis, Nasal obstruction

Nasal conidiobolomycosis also called as entomphthoromycosis is a rare fungal infection caused by *Conidiobolus coronatus*. The fungus is present in soil and decaying vegetations [1]. It generally affects the upper respiratory tract, but rarely can affect the nose and subcutaneous tissue of face. Here, we report a case of farmer working in Orissa, who presented with the swelling of nose and after much dilemma was found to be suffering by *Conidiobolus* infection.

A 45-year-old male, farmer in Orissa presented to OPD with a progressive painless swelling over nose for duration of six months [Table/Fig-1]. Apart from right side nasal obstruction, there was no other specific complaint. Contrast Enhanced Computed Tomographic (CECT) scan of nose and paranasal sinuses revealed bilateral maxillary sinusitis [Table/Fig-2] and nasal endoscopic examination was found to be normal. Decision to take a skin biopsy was taken which showed superficial layer of keratinizing stratified squamous epithelium and dense neutrophilic infiltrate in dermis with thin wall fungal elements amidst granulomas surrounded by Splendore-Hoepli phenomenon [Table/Fig-3] and after 72 hours growth on Sabouraud Dextrose Agar (SDA), the isolate of *Conidiobolus coronatus* was obtained. The diagnosis was

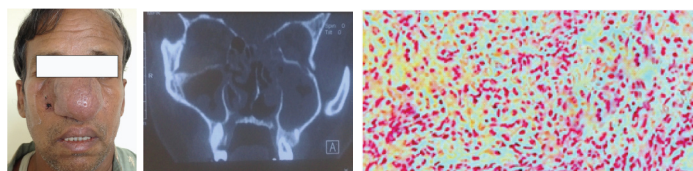
further confirmed by light cyclor PCR assay which accomplishes identification by PCR amplification and sequencing of DNA. Patient was started on itraconazole 200mg/day and potassium iodide 8 drops three times a day for a month and kept on regular follow-up with improvement seen as a reduction in size of the primary lesion.

DISCUSSION

Conidiobolomycosis occurs mainly in tropical regions of Africa, South and Central America and South East Asia including India. It is generally seen in farmers and other outdoor occupations. The 3 species of the order Entomophthorales that cause conidiobolomycosis in humans and animals are *C.coronatus*, *C. incongruus* and *C.lamprauges*. Disease mainly affects the upper respiratory tract leading to a granulomatous reaction ultimately leading to formation of hard nodules over skin surface. The treatment of the disease is not well defined at present. A definitive diagnosis of rhinofacial entomophthoromycosis requires histopathologic demonstration of the etiologic agent and its isolation in culture [2,3]. The disease remains to be under reported due to the lack of clinical suspicion and lack of culture facilities. Our patient had responded well and is under regular follow-up with no systemic side effects of the treatment so far.

REFERENCES

- [1] Pfaller MA, Diekema DJ. Unusual fungal and pseudofungal infections of humans. *J Clin Microbiol.* 2005;43:1495-504.
- [2] Das P, Vijay MK, Joshi P, Yadav R, Singh G. Histological identification of Entomophthoromycosis in biopsy samples is required. *Indian J Pathol Microbiol.* 2014;57(3):514-16.
- [3] Chowdhary A, Randhawa HS, Khan ZU, Ahmad S, Khanna G, Gupta R, et al. Rhinofacial entomophthoromycosis due to *Conidiobolus coronatus*. A case report and an overview of the disease in India. *Medical Mycology.* 2010;48:870-79.



[Table/Fig-1]: Showing the clinical image of the patient. **[Table/Fig-2]:** Showing the CECT scan of nose and paranasal sinuses of patient having bilateral maxillary sinusitis. **[Table/Fig-3]:** Histopathologic image of the patient showing dense neutrophilic infiltrate in dermis with fungal elements surrounded by splendore-hoepli phenomenon.

PARTICULARS OF CONTRIBUTORS:

1. Senior Resident, Department of Ear, Nose and Throat, Maulanaazad Medical College, New Delhi, India.
2. Senior Resident, Department of Ear, Nose and Throat, Maulanaazad Medical College, New Delhi, India.
3. Senior Resident, Department of Ear, Nose and Throat, Maulana Azad Medical College, New Delhi, India.

NAME, ADDRESS, E-MAIL ID OF THE CORRESPONDING AUTHOR:

Dr. Nikhil Arora,
D-55 Arya Nagar Apartments, I.P. Extension, Patparganj, New Delhi, India.
E-mail: for_nikhilarora@yahoo.com

FINANCIAL OR OTHER COMPETING INTERESTS: None.

Date of Submission: **May 17, 2016**
Date of Peer Review: **Jun 09, 2016**
Date of Acceptance: **Jul 27, 2016**
Date of Publishing: **Dec 01, 2016**